Gurucharanam Saranam

Santhigiri

Santhigiri Ayurveda Medical College
NEWSLETTER

Vol: 02 / Issue : 05 / February 2020 / Monthly Publication

Editorial

Gurucharanam Saranam

On this auspicious occasion of "Mahaas`ivaraatri" we, the family of Santhigiri Ayurveda Medical College, Palakkad pray the Lord S`iva for His blessings on all beings and wish all of us to be enlightened with the inner Self.

In recent times it is observed that there is a rapid increase in number of C-sections worldwide mostly in developed nations. The latest data from 150 countries shows that 18.6% of all deliveries occur by C-section and in Latin America it is as much as 40.5%. In India also such trend is observed. Such unhealthy practice is due to many misconceptions among the public on C-section as a painless one, safe for baby and mother and the most important factor is lack of medical ethics among the medical professionals. Its scientifically established that the natural vaginal deliveries are safer and healthier for both mother and the child.

Let me mention some of the facts on importance of natural vaginal delivery in context of Gut Microbiota. Besides social, cultural, biological and medical reasons practice of natural vaginal delivery is desirable, unless until C - section is indicated medically as -during this vaginal delivery the child is exposed to vaginal and perianal microbiota of mother which is the primary source of gut microbiota of the child. It plays a vital role in maintaining the health during early days and later period of life. Previously much importance was given to germ free status of human body and microbes were understood as causative factors of diseases. But the fact is that every surface of human body that is exposed to external environment is colonized by Microbiota. The most heavily colonized organ is Gastro-intestinal tract with more than 70% of total human microbiota. The human gut is one of the largest organs with 200 square meter surface area and rich in nutrients for microbiota. The gut Microbiota contains 10^{14} bacteria cells, ten times more than the total human cells. In addition to the bacteria, gut microbiota contains yeast, fungi, viruses, phages, archeae. Now gut microbiota is considered as essential organ, which weighs about 2 kilograms. Microbiotic composition and function varies according to location, age, sex, race, diet etc.

The latest researches state that the human gut microbiota contributes a lot in host metabolism and a potential source of novel therapies. It is understood that this microbiota is having specific role in energy metabolism and homeostasis of glucose and lipids. Hence the disturbed state of it results in development of disease conditions like cardiovascular diseases, liver diseases, obesity, inflammatory bowel diseases, cancer, diabetes and also neuropsychiatric diseases.

Among the numerous metabolites produced by microbiota, some of them to mention here are folates, biotin, riboflavin, cobalamin, vit. K, indoles, secondary bile acids, trimethyalamine N-oxide, short chain fatty acids and also neurotransmitters like serotonin, GABA.

Widespread use of antibiotics and chemotherapy like procedures result in disturbance and destruction of this symbiotic system and various pathological conditions. Proper understanding of this mutual dependence of all beings in this universe is very essential in maintaining harmony and health. Though this theory and understanding of Gut-microbiota is the latest one in modern medicine, such understanding and its applications can be observed in aayurveda in various contexts like annakalpana, anupaana, patthyakalpana, saatmya, samsarjanakrama in panc'akarma. These applied aspects in aayurveda can be the guiding principles for the contemporary health sciences for further holistic and comprehensive research. We hope ethical and humanitarian medical practices prevail over the unethical and unhealthy ones.

Om Sahanaavavatu, Sahanaubhunaktu,
Sahaveeryam karavaavahai
Tejasvinaavadheetamastu maa vidvishaavahai/
Om s'aanti s'aanti s'aantih

Dr. G. Nagabhushanam
Chief Editor

CONTENTS

1. Perthes' Disease - Dr Suchith M S
2. Kshaarasootra In S'alyaja Naad'eevran'a wsr Pilonidal Sinus - A Case Study - Dr Arun Babu
3. Medical Bulletin
4. Events

Perthes Disease

Dr. Suchith M.S
Professor&H.O.D.
Department of ShaalaakyaTantra

Perthes disease is a type of crushing osteochondritis, where the whole or a part of the femoral head becomes avascular.

Aetiology

There are a few conditions which may diminish or block the arterial supply to the head of the femur. These causes are -

(a) Traumatic effusion- Effusion following trauma increases the intracapsular pressure and may hamper the blood supply to the head of the femur as the lateral epiphyseal blood vessels constrict under pressure. History of trauma can be elicited in more than half of the cases of Perthes disease.

(b) Inflammatory conditions.-An Inflammatory condition of the hip eg:synovitis, septic arthritis may lead to this condition. In early Perthes' disease there is inflammation of the synovium with increased fluid.

(c) Epiphyseal dysplasia.- Irregular ossification, as happened in epiphyseal dysplasia may cause this condition.

(d) A few medical conditions e.g. Rickettsial infections, Caisson's disease and Gaucher's disease are other causes which may lead to Perthes' disease.

(e) Metabolic, endocrine and constitutional factors have been blamed with little definite evidence.

Pathology

Pathology of Perthes' disease is best described under two stages.

STAGE I (Stage of avascular necrosis).- As described earlier it is a disease of ischaemia of the femoral head. Ischaemia affects a part or whole of the femoral head. The avascular head looks dense on X-ray and it does not grow normally, so it becomes smaller than the non-affected side. The cartilaginous envelop of the head is independently nourished by the synovial fluid and it continues to enlarge. So the small dense head is covered with the well developed cartilage. In X-ray this is evident by increase in joint space.

STAGE II (Stage of regeneration).- Blood vessels gradually grow through the metaphysis and supply the neck and head of the femur. As the new vessels virtually creep into the dead head, the process is called regeneration by creeping substitution. As the neck and head become more vascularised, they become soft and look rarefied on X-ray. The soft bone squashes easily and bends easily, so the neck becomes thick and angled to cause coxa vara. Due to localised hyperaemia cysts appear in the metaphysis. When blood vessels reach the femoral head, the dead bone is absorbed piecemeal. So patchy rarefaction becomes evident in the femoral head. In fact new blood vessels to the femoral head come from the periphery, which revascularize first, so the peripheral part becomes soft in the beginning leading to distortion of the shape of the head. Gradually revascularisation spreads towards the centre of the head, eventually new bone of normal density is deposited, but the head of the femur remains permanently flat and cannot gain its normal round appearance

GRADING can be done on radiological grounds into four groups. In grade I, only half the head is necrotic and no collapse occurs. In grade II, more than half the head is involved but there is still no collapse. In grade III, most of the head becomes necrotic and there is collapse, In grade IV, whole of the head becomes ischaemic and necrotic, collapse is also severe. While grade I and grade II require no treatment or simple bed rest or traction, Grade III and grade IV indicate worse prognosis and must need 'containment treatment'.

Complications.- As the head remains permanently flat, this will obviously cause an early osteoarthritis of the hip, which is the complication causing concern to the patient.

Clinical features-

(i) Age.- There is a definite age of Perthes' disease and that is between 5 to 10 years of age

(ii) Sex.- This condition is 4 times commoner in boys, as this condition is often caused by trauma.

Symptoms.- Ache and limp are the two symptoms which start almost simultaneously. The pain in the hip is often slight and intermittent. When the irritable stage is passed, pain may be absent. Patient may complain of slight rise of temperature. Pain may be referred to the knee joint. Pain, limp and rise of temperature often confuse this condition with tuberculosis of the hip. There may be associated urogenital anomaly. Symptoms are in fact not much in accordance with the gross X-ray changes.

Physical signs.-

Inspection- Except slight wasting, particularly of the buttock, there is hardly any abnormality detected

Palpation- On careful palpation, the greater trochanter will be felt slightly higher than normal. Trendelenburg's test is positive.

Movement- When the hip is irritable, all movements are limited at the extremes. Limitation of internal rotation is particularly characteristic, so is abduction in flexion. Full extension is also not possible due to hip flexion contracture. Other movements are painless and their ranges are full.

Radiographic appearance (X-ray)-

STAGE I (AVASCULAR NECROSIS).-

(a) The joint space is increased.

(b) The femoral head is placed more laterally.

(c) The femoral head shows increased density - which becomes granular in the beginning and then becomes uniform.

(d) The femoral head shows flattening and patchy fragmentation.

(e) A linear radiolucency can be noticed which separate a small segment of head from the rest. This is known as Caffey's line and almost mimics a fracture line.

STAGE II.- In this stage the dense head is revitalized.

(i) The neck becomes wide and curved causing coxa vara

(i) There is a band of rarefaction at the metaphysis.

(ii) There are cystic appearance with surrounding sclerosis at the metaphysic.

(iv) The sclerosed head becomes fragmented.

(v) The head remains still flat.

(vi) A change in the acetabular cavity is also noticed in the form of increased distance between the medial pole of the head and the floor of the cavity. This is because the ligamentum teres becomes grossly swollen and congested

(vii) The acetabular cavity is hollowed out abruptly Areas of irregular condensation or density may be noticed but the appearance is ill-defined.

Differential diagnosis

1. Tuberculosis of the hip joint.

2. Transient synovitis which occurs most commonly at the age of 3 to 8 years. The avascular necrosis of Perthes disease which becomes obvious in X-ray is not found in this condition.

3. Irritable hip.

Treatment

According to the X-ray findings Perthes' disease can be divided into 2 categories -

1. When less than half of the head is involved by the disease -in this case the prognosis is good and the treatment is simple traction.

2 When the X-ray shows involvement of more than half of the head. In this case containment treatment is required.

1. TRACTION- When the hip is irritable and the child complains of pain, he should be put to bed and skin traction has to be applied to the affected leg.

2. CONTAINMENT - The recent theory is that for better revascularization, the femoral head should be well contained within the acetabulum. Previously the patients were not allowed to bear weight, but the present evidence is in favour of weight bearing as it is not only harmless but probably helps in better vascularisation of the head of the femur. Containment can be achieved by holding the hips widely abducted in plaster on in a polythene splint. This position should be maintained for at least a year. The aims of treatment are (i) to place the femoral head deep within the acetabulum: (ii) To avoid acetabular rim pressure on the head; (iii) to equalise the pressure on the articular cartilage; (iv) To diminish pressure on the acetabulum while walking and (v) to promote formation of a round head within a normal acetabulum. With the splint or plaster on, the patient can walk, though with difficulty. A few operations have been suggested for better containment. These are :

(a) Salter's innominate osteotomy - Salter advocated that this operation is quite effective in Perthes' disease as it places the femoral head deep within the acetabulum.

(b) Intertrochanteric osteotomy allows the head and neck to fall into a varus position. This is also called varus osteotomy. It has got a disadvantage that it shortens the limb to a slight extent. After operation plaster is used for immobilisation till osteotomy site is united. This takes about 2 to 3 months. After this the child is allowed to move freely.

Aayurvedic Approach

Majority of Perthes disease presents with sandhi-asthi-gata-vaata lakshan'a.

In-patient treatments followed in our hospital are:

Dhaanyaamladhaara

Pradeha with kolakulatthaadi coor'na in curd

Kukkut'aan'd'a pin'd'a sveda

Kukkut'a and Aja maamsa pin'd'a sveda and Upanaaha bandage with the same.

Patient will be discharged after 21 days and the same may be repeated after 4 or 6 months if necessary, based on prognosis.

Internal medication comprises of combination of medicines among the following:

Marma kashaayam

Caatilin~ga tailam

An'd'a tailam

Can'd'amaaruta cendooram

Guggulutiktaka ghr'tam

Kshaarasootra In S'alyaja Naad'eevran'a wsr Pilonidal Sinus - A Case Study

Dr. Arun Babu
Assistant Professor
Dept.of S'alyatantra

Abstract

Pilonidal sinus (Naad'ee vran'a) is an acquired condition and seen in adult males and hardly seen in females. 'Pilonidus' means nest of hairs. Hairs break off due to friction between clothes and body and get collected in the gluteal cleft and enter the openings of the sudoriferous glands. After initial entry dermatitis and inflammation start around the loose hairs and sinus will be formed further. This disease is recurrent in nature which makes it more difficult for treatment. It thus produces inconvenience in routine life. The concept of kshaarasootra has been explained in the context of Naad'ee vran'a (sinus) by Aacaarya Sus'r'uta. In this study, the patient presented with complaints of pain and foul smelling discharge from low back which was diagnosed as pilonidal sinus. The patient was not willing to undergo surgery and thus opted for the kshaarasootra. The patient was treated on OPD basis with weekly change of thread. The patient recovered well with complete excision of the tract within a span of 10 weeks.

Key words- Pilonidal sinus, Naad'ee vran'a, Apaamaarga Kshaarasootra

Introduction

Pilonidal sinus is a common condition which we see in current surgical practice. This is a raising problem and challenge to practicing surgeons. It is a sinus track which commonly contains hairs. It occurs under the skin between the buttocks (the natal cleft) at a short distance above the anus. The sinus track goes in a vertical direction between the buttocks. Most cases occur in young male adults. The origin of Pilonidal disease is not fully understood, although hormonal imbalance, presence of hair, friction and infection are often implicated. The most commonly used therapy is surgery including wide excision and healing by secondary intention. However, post operative recurrence following surgery is high, leading to frequent and time-consuming wound care. Hence, there is a need to evaluate the role of the other alternative/ innovative techniques for the management of this challenging disease so as to minimize recurrence ,make it cost effective with improved acceptability& minimum hospitalization. 'Sus'ruta Samhita' describes a condition s'alyaja naadee vran'a which is similar to 'Pilonidal sinus'. Sus'ruta has advocated a very unique, minimally invasive treatment i.e. 'kshaara sootra' procedure for management of naad'ee vran'a. Kshaara sootra is a medicated thread (kshaara sootra, derived from Sanskrit word- kshaara means, to cut; sootra means thread) coated with herbal drugs and rendered alkaline. The introduction of kshaara sootra into fistulous tract gradually dissolves the fibrous tissues, drain the pus and enhance the granulation in the tract.

Patient details

A 35 year old male patient presented with complaints of pain and foul smelling discharge from low back region between the buttocks since 15 years. Initially he noticed mild swelling at natal cleft with intermittent dull aching pain which was there for 6 days . Later he noticed foul smelling pus discharge associated with mild itching in that area. He used to feel discomfort in this region during sitting and bending. He neglected it even though it used to interfere with his daily activities. Whenever there was little injury to the area, pain and bleeding were noticed for which he consulted a local physician to get rid of pain.

Two months ago, he noticed mild swelling at right side of natal cleft with intermittent dull aching pain which was followed by foul smelling pus discharge. Symptoms used to aggravate by travelling on his bike and profuse sweating.

Examination of sinus -

Inspection

1) Number of sinus- 6 Sinuses

2) Position of sinus:

-2 Primary openings in the midline of natal cleft just above the buttocks.

-4 Secondary openings seen right laterally.

3)Opening of the sinus

-Presence of tuft of hairs seen

-Margin – normal.

4) Discharge- Pus discharge present

5) Surrounding Skin-

-Inflammation - present.

-Scars – Absent

6) Smell- Foul smelling discharge.

Sinus probing:

Two primary sinuses were interconnected with a depth of 2cm directed downwards. The secondary sinuses right laterally were connected to the primary sinuses and inter connected with each other. There was blood mixed pus and hair on withdrawal of the probe.

P = Primary sinus

S = Secondary sinus

P1- P2 interconnected.

P1- S1interconnected

P2-S4 interconnected

S1-S2interconnected

S3-S4interconnected

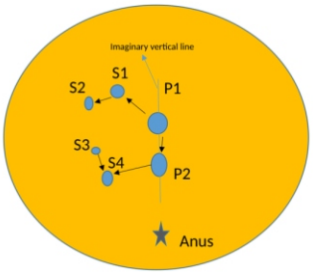

Laboratory investigations –

Hb – 15.3gm%

TC – 9680 cells/cubic mm3

Bleeding time – 2min 05sec

Clotting time – 4min 45 sec.

Prothrombin time – 12.8 sec.

Activated partial thromboplastin time – 34.6sec.

Random blood sugar – 104mg/dl.

HBsAG – Non reactive.

HIV 1 & 2 – Non reactive.

ESR – 22mm/Hour.

ECG – Normal.

CXR – PA view – Normal.

Application of Kshaara sootra

The kshaara sootra prepared with Apaamaarga (Achrynthes aspera) as per standard protocol was used. Patient was advised to maintain proper local part preparation and general hygiene before application of kshaara sootra. Patient was placed in knee elbow position and after aseptic preparation of the part, probing was done under local anaesthesia. Probe was passed into the P1 opening; gradually extended to the other opening and before taking it out, a sterile plain surgical linen thread Barbour number 20 was threaded into the eye of probe, present at tail end and then probe was taken out through P2. Same procedure was repeated between S1 – S2 and S3 – S4 (Primary threading). One week later, the old kshaara sootra was replaced by new one by railroad technique. After replacement of the kshaara sootra, the patient was advised to continue his normal routine work .The kshaara sootra was changed weekly.

Results

There was considerable changes found on various parameter which was as follows: -

Assessment during the treatment

SlNo.	Thread change date	Discharge	Pain	Tenderness	Itching
1.	8th Dec 2018	+++	+++	+++	++
2.	10th Dec 2018	+++	+++	+++	++
3.	19th Dec 2018	++	+++	+++	++
4.	24th Dec 2018	++	+++	++	++
5.	7th Jan 2019	++	++	++	++
6.	14th Jan 2019	+	++	+	+
7.	21st Jan 2019	+	+	+	Absent
8.	27th Jan 2019	+	+	+	Absent
9.	3rd Feb 2019	+	-	-	Absent
10.	10th Feb 2019	-	-	-	Absent
11.	18th Feb 2019	-	-	-	Absent

The complete excision of primary tract was achieved in span of 7 weeks and for secondary tract exicision achieved in 10 weeks.

Discussion

The management of pilonidal sinus in an effective manner has always been a challenge to the surgeons. The conventional operative treatment of pilonidal sinus is to lay open or completely excise the fistulous track and allow healing by open granulation. The kshaara sootra therapy in pilonidal sinus can be considered as preferable method of treatment for the following reasons –

1. It is technically easy, safe and simple method. It can be carried out in the outpatient department, as most of the cases do not

require any anaesthesia also. It is considered as cost-effective treatment as compared to others.

2. It does not require hospitalisation and patients could continue with their normal routine work, thus patient's social, psychological and economic status is not disturbed during the treatment.

3. The rate of recurrence after the treatment is negligible as compared to its various other sections and surgical management.

4. It is an ideal management for the patients of old age or having respiratory or cardiovascular diseases and or otherwise unfit for surgery.

5. No systemic side effects are encountered with kshaara sootra therapy, although transient infection, local burning sensation, mild pain, itching and slight indurations are observed, which rarely need medication.

6. Post-operative tissue damage and scarring are minimal. The kshaara sootra therapy, a unique method of drug delivery is most appropriate for healing the fistulous track and it offers an effective, ambulatory and safe alternative treatment in patients with pilonidal sinus .

Conclusion

The results obtained were found very encouraging. Hence, application of kshaara sootra can be effective in the management of pilonidal sinus.

Medical Bulletin

Novel coronavirus outbreak

Novel coronavirus (2019-nCoV) outbreak was first reported from Wuhan, China, on 31 December 2019 which later spread to 24 countries.Corona viruses are zoonotic and common signs of infection include respiratory symptoms, fever, cough, shortness of breath and breathing difficulties. In more severe cases, infection can cause pneumonia, severe acute respiratory syndrome, kidney failure and even death.

Standard preventive precautions

1.Wash hands with soap and water or alcohol-based hand rub.

2.Practice respiratory hygiene and follow cough etiquette.

3.Maintain social distancing of at least 1 metre (3 feet) distance with people with fever.

4.Avoid touching eyes, nose and mouth with contaminated hand.

5.If one have fever, cough and difficulty breathing, seek medical care early.

6.Practice general hygiene measures when visiting live animal markets or animal product markets

7.Avoid consumption of raw or undercooked animal products.

8.Use proper personal protective equipments.

9.Take care of unnecessary travel and public gathering.

10.If one become sick while traveling share travel history with health care provider.

Sanskrit Alphabets
with English Transliteration Key

अ	आ	इ	ई	उ	ऊ	
a	aa	i	ee	u	oo	
		ए	ऐ	ओ	औ	
		e	ai	o	au	
ऋ	ॠ	ऌ		अं		अः
r'	rr'	l'		m		h
क	ख	ग	घ	ङ		
ka	kha	ga	gha	n~		
च	छ	ज	झ	ञ		
ca	cha	ja	jha	n`a		
ट	ठ	ड	ढ	ण		
t'a	t'ha	d'a	d'ha	n'a		
त	थ	द	ध	न		
ta	tha	da	dha	na		
प	फ	ब	भ	म		
pa	pha	ba	bha	ma		
य	र	ल	व			
ya	ra	la	va			
श	ष	स	ह		क्ष	ज्ञ
s'a	sha	sa	ha		ksha	jna

Events

Applied Sanskrit in Understanding Aayurveda

A guest lecture was organised on the topic "Applied Sanskrit in Understanding Aayurveda" on 06th Jan 2020 at the college auditorium by Dr. Ramadas.P. (Dept of Samhitha Siddhanta, Amrita School of Aayurveda, Kollam).

Medical camp - Lion's School

A medical camp was conducted on 5th Jan 2020 at Lion's Higher Secondary School, Palakkad in coordination with Lion's club International, Palakkad. The camp was lead by Dr Manjusha B along with a team of supporting staff and house surgeons.

Third Year Tour Program

The students of Third Year BAMS visited Vagamon and Ramakalmedu as part of the College Tour Program from 10th to 13th January 2020.

Anti Narcotic Program - Oath Taking

The students, teaching and non teaching staff of the college and hospital participated in the Oath Taking Ceremony which was conducted as part of the Kerala Government's Anti-narcotic Program in the College Premises on 16th January 2020.

National Road Safety Week 2020

NSS Unit conducted a Flash mob on anti narcotic awareness and road safety measures on 17th January 2020 at Stadium Bus Stand, Palakkad in connection with observance of 31st National Road Safety Week from 11th to 17th January 2020.

Ganitholsavam 2020

The House surgeons Conducted a class on "Ganitholsavam 2020" for the benefit of the students of Senior Basic School, Olassery on the topic "Health & Mathematics" on 17th January 2020 by Department of Agada Tantra.

Nature Club Camp

Second Year BAMS students and Nature club members participated in the Nature Education Camp at Parambikulam Tiger Reserve on18th January 2020. Dr. Sumam E and Dr. Sneha MS lead the Team.

Svasta Vr'tta Visit

As part of study tour, Third Year BAMS batch visited Nila Nature Cure and Ayurveda Centre, Mayannur on 22nd January 2020. Dr. Deepty Nair and Dr. Kiran K Prasad accompanied the students.

Republic Day Celebrations

The Flag Hoisting Ceremony was held in the College Campus on 26th January 2020 as part of the 71st Republic Day Celebrations.Dr. G. Nagabhushanam delivered the republic day message. The students, staff and the NSS volunteers of the college NSS unit participated in the ceremony.

Medical Camp - BPCL

A medical camp was conducted at the BPCL outlet , Palakkad on 29th January 2020. Dr. Santhosh Kumar led the team of doctors and supporting staff.

Martyr's Day

Martyr's day was observed on 30th January 2020 paying tribute to the father of the nation, Mahatma Gandhi. A two minute silence in memory of Indian martyrs was observed in the campus at 11 AM.

Samskrita S'ibiram

Samskrita basha sambhashana S'ibiram for first year BAMS students was inaugurated on 3rd February 2020. The chief guest for the event was Shri. Mohanan Master from Sanskrit bharathi. The event was chaired by Dr. G Nagabhushanam. the students and teachers participated in the inaugural session.

Novel Corona Virus Awareness

An Awareness Class on Chickenpox & Novel Corona Virus Outbreak was conducted by the faculty of Department of Svasta vr'tta & Yoga which was followed by a skit on Cancer Awareness by the students of the college at the seminar hall on 5th February 2020.

Our Address :-

Santhigiri Ayurveda Medical College
Olasseri P.O, Kodumba (via)
Palakkad, -678 551
Kerala, India
Ph: +91 491 2574574
www.samc.santhigiriashram.org
www.santhigirionline.com